

Retrospective Case Series Analysis: Clinical and Functional Outcomes of Dacryocystorhinostomy Surgery

ABSTRACT

Background: Dacryocystorhinostomy (DCR) is the surgical gold standard for treating nasolacrimal duct obstruction (NLDO), creating a direct passage between the lacrimal sac and nasal cavity to restore tear drainage. Despite high success rates, failures can occur due to anatomical or functional factors. This five-year retrospective study analyses 50 DCR cases, focusing on demographics, causes of failure, intranasal pathologies, and outcomes of revision procedures with silicone intubation.

Methods: A retrospective review of 50 consecutive DCR surgeries was conducted at a tertiary care centre. Data regarding demographics, surgical approach, failure causes, and associated intranasal findings such as deviated nasal septum (DNS) and adhesions were collected. Revision outcomes with silicone intubation and adjunct Mitomycin C (MMC) were also evaluated. Both adult and paediatric cases were included.

Results: Among 50 patients, 45 were adults and 5 were paediatric (ages 5–11); 33 were females and 17 males. Thirty-five surgeries were left-sided and 15 right-sided, all with silicone intubation. The overall failure rate was 10% (5 cases). Three failures were related to high DNS and resolved after septoplasty; one due to intranasal adhesion was corrected endoscopically, and one was managed by nasolacrimal probing. Four revision DCRs with MMC achieved successful outcomes. Paediatric patients showed good anatomical response and recovery.

Conclusion: Comprehensive nasal evaluation and ENT collaboration are essential for identifying intranasal causes of DCR failure. Silicone intubation and adjunctive MMC improve success rates, while postoperative endoscopic follow-up ensures durable results.

Key words: Dacryocystorhinostomy, deviated nasal septum, nasolacrimal duct obstruction, revision surgery, silicon tube insertion

INTRODUCTION

Dacryocystorhinostomy (DCR) is a time-tested procedure for bypassing obstruction of the nasolacrimal duct, restoring lacrimal drainage directly into the nasal cavity. The surgery involves creating a mucosal-lined bony ostium between the lacrimal sac and nasal mucosa, with or without stenting. DCR can be performed through external or endoscopic endonasal approaches. Both techniques offer high success rates, generally reported between 85% and 95%, with paediatric cases occasionally demonstrating slightly higher anatomical success due to more pliable tissues and less fibrosis.^[1,2] However, surgical failure, although relatively infrequent, remains a significant concern. Causes of failure include anatomical factors such as a deviated nasal septum (DNS), nasal synechiae, granulation tissue formation, or improper localization of the osteotomy. Functional failures, characterized by patent ostia but persistent symptoms, may also result from inadequate mucosal apposition, canalicular issues, or valve dysfunction.^[3–5] This retrospective case series evaluates 50 consecutive DCR surgeries performed at a single institution over five years. We assess the demographic profile, surgical outcomes, and specific causes of failure. Additionally, we analyse revision strategies and discuss the role of adjunctive measures such as silicone tube intubation and Mitomycin C. Our findings are

contextualized within the existing literature to offer evidence-based recommendations for improving surgical outcomes in both adult and paediatric patients.

Smita Gavade¹, Shruti Madhani², Minu Ramakrishnan³, Omkar Telang⁴

¹Assistant Professor, ²Junior Resident, ³Professor, ⁴Professor and Head of Department. Department of ophthalmology, K. J. Somaiya medical college and research centre.

Corresponding Author:

Smita Gavade, Fellowship in oculoplasty and ocular oncology. Assistant Professor, Department of ophthalmology, K. J. Somaiya medical college and research centre.

E mail: smitagavade86@gmail.com

MATERIALS AND METHODS

Study Design and Patient Selection

This retrospective case series includes 50 consecutive patients who underwent DCR procedures from 2020 to 2025 at a tertiary care centre.

Inclusion Criteria:

1. Patients with symptomatic nasolacrimal duct obstruction confirmed by sac syringing.

- Both primary and revision cases included.
- Paediatric and adult cases.

Exclusion Criteria:

- Canalicular obstruction or trauma-related NLDO.
- Patients lost to follow-up before 6 months.

Surgical Technique: All patients underwent external DCR performed by a single experienced surgeon. Silicone tube intubation was used in all cases to maintain ostial patency, consistent with literature recommending stenting in both primary and revision settings.^[2]

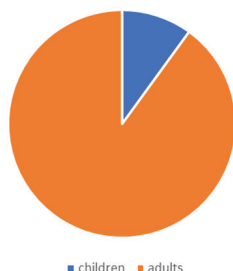Revision DCRs operated elsewhere, intraoperative application of 0.02% Mitomycin C for 2 minutes was incorporated to the osteotomy site to reduce fibrosis. Endoscopic evaluation was employed pre- and post-operatively, especially in revision cases or suspected failures.

Data Collected:

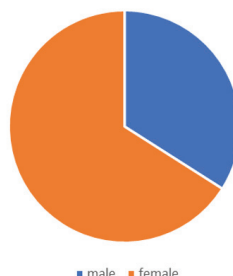
- Paediatric vs. adult categorization
- Sex distribution
- Primary vs. revision surgery
- Postoperative complications
- Success vs. failure outcomes
- Management of failed cases

RESULTS

The study comprised 50 participants, out of which 5 were children of age group between 5- 11 years representing 10% of total sample and 45 were adults constituting 90% of total sample.

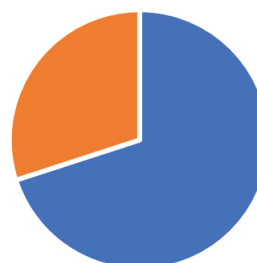

The gender distribution among the participants revealed that out of 50 participants, 33 were female representing 66% of the sample while 17 were males representing 34% of the cohort. This indicates majority of females underwent the procedure.



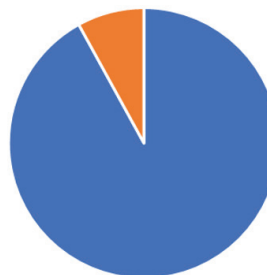The majority of patients were adults (90%), with a female predominance (66%). All procedures included silicone tube intubation. Paediatric cases were modified according to anatomical considerations, with no intraoperative complications noted.

In our study, out of 50 participants, 35 left sided Dacryocystorhinostomy was performed which comprises of 70% of total sample while only 15 right sided dacryocystorhinostomy was performed which comprises of 30% of total sample.



■ Left sided DCR ■ Right sided DCR

In our study, out of 50 participants, 4 individuals underwent Re-DCR procedure which was operated elsewhere who came to us with persistent epiphora and complete mucoid regurgitation on sac syringing that constitute of 8% of total sample while 46 participants underwent primary DCR surgery which represents 92% of total sample.



■ Primary DCR ■ Re-DCR

Revision Surgery Outcomes: Four patients underwent revision DCR with intraoperative Mitomycin C application. All cases achieved symptom resolution and patent irrigation at follow-up.

Failure Analysis: In our study out of 50 participants, five patients (10%) experienced surgical failure, defined by persistent epiphora and/or blocked irrigation at follow-up.

- High Deviated Nasal Septum (n=3): These cases had a high DNS compressing the osteotomy site, compromising drainage. Septoplasty was performed following initial DCR failure, leading to symptomatic improvement.
- Functional Failure Resolved by Probing (n=1)
- Intranasal Adhesions (n=1): Synechiae were identified during endoscopic evaluation and released endoscopically. Patency was restored.

DISCUSSION

This case series demonstrates that the use of silicone tube intubation in all cases likely contributed to the high patency rate, consistent with current recommendations for enhancing long-term outcomes. Intubation maintains the neo-ostium during healing and reduces the risk of premature closure, especially in patients with scarring tendencies.^[2]

While DCR is generally highly effective, anatomical abnormalities—particularly high DNS and intranasal adhesions—can significantly compromise surgical success. Our 10% failure rate aligns with published literature, which cites DNS as a common predisposing factor for DCR failure.^[3,4]

In this study we also saw there was female preponderance than males due to anatomical and possibly hormonal factors, with studies showing a higher percentage of female patients with nasolacrimal duct obstruction (NLDO). The nasolacrimal duct, which drains tears, is generally narrower and shorter in women, leading to more frequent obstructions and thus more DCR procedures.^[5]

Paediatric patients, though comprising a small subset, demonstrated good anatomical success.

Endoscopic re-evaluation was instrumental in identifying the precise cause of failure, guiding targeted intervention. For example, in cases of high DNS, septoplasty enabled improved access and ostial patency. The role of adjunctive 0.02% Mitomycin C for 2minutes in revision cases was notable, echoing other studies that support its antifibrotic properties in reducing scarring and restenosis.^[5-6]

Our findings underscore the value of preoperative otolaryngologic consultation in all DCR candidates, particularly those with nasal obstruction symptoms or a known history of DNS. Identifying and addressing these issues preoperatively can significantly improve surgical outcomes.

CONCLUSION

This five-year case series highlights the continued relevance of anatomical assessment, individualized management, and evidence-based adjuncts in optimizing DCR outcomes. Key takeaways include:

Preoperative nasal assessment and ENT collaboration are crucial to identifying and managing contributing intranasal pathologies.

Silicone tube intubation remains a cornerstone of both primary and revision DCR for maintaining ostial patency.

Adjunctive Mitomycin C (0.02% for 2minutes) use in revision surgeries supports tissue healing and improves success rates.

Endoscopic re-evaluation offers precise identification of failure causes and allows for minimally invasive corrective interventions.

This comprehensive approach—integrating careful preoperative planning, standardized surgical techniques, and prompt failure management—can significantly enhance outcomes in both adult and paediatric DCR patients.

How to cite this article: Gavade S, Madhani S, Ramakrishnan M, Telang O. Retrospective Case Series Analysis: Clinical and Functional Outcomes of Dacryocystorhinostomy Surgery. *Bombay Hosp J* 2024;66(4):11-13.

Conflicts of Interest: None. **Source of Support:** None.

REFERENCES

1. Coumou AD, et al. Endoscopic dacryocystorhinostomy: long-term experience and outcomes. *Acta Ophthalmol.* 2017;95(5):488–493.
2. Ghasemi H, et al. External Dacryocystorhinostomy; Success Rate and Causes of Failure. *Iran J Otorhinolaryngol.* 2017;29(93):189–194.
3. Baek JS, et al. Cause and Management of Patients With Failed Endonasal DCR. *Clin Exp Otorhinolaryngol.* 2016;9(3):232–237.
4. Keren S, et al. Endoscopic dacryocystorhinostomy: reasons for failure. *Eye.* 2020;34:900–905.
5. StatPearls. Dacryocystorhinostomy. Treasure Island, FL: StatPearls Publishing; 2023.
6. Suzanne K Freitag, et al. Use of Mitomycin C in Dacryocystorhinostomy: A Report by the American Academy of Ophthalmology, 2023
7. Eyewiki.org: Dacryocystorhinostomy. American Academy of Ophthalmology.