

Acute Febrile Illness with Skin Rash with Multiorgan Affection Presented as Scrub Typhus – A Case Report

ABSTRACT

Aim: The aim of the study is to diagnose and treat the patient with acute febrile illness and multiorgan failure affection who presented as scrub typhus. **Background:** Scrub typhus fever is a disease caused by *Orientia tsutsugamushi*. **Case Description:** This is a case of adult male patient who has gone for picnic at hilly area and who presented after 5 days with acute febrile illness and deteriorated with skin rash and multiorgan affection. His tropical fever panel investigations were normal and found to have high titer of Weil–Felix test and polymerase chain reaction for rickettsia was positive. He responded well with doxycycline injection and was discharged. **Conclusion:** Scrub typhus is characterized by skin rash initially maculopapular, progressing to petechial and spreading centripetally in patient with high fever, myalgia, and headache with supportive epidemiologic or exposure history. Classical triad includes morbilliform eruption plus fever plus necrotic papule (eschar at the tick bite site) should prompt diagnosis of scrub typhus infection. **Clinical Significance:** With prompt diagnosis and identifying the main characteristic features of scrub typhus such as eschar is important to identify so that the appropriate treatment can be started. Doxycycline is the mainstay treatment.

Key words: *Orientia tsutsugamushi*, Skin rash with eschar formation, Weil–Felix test

INTRODUCTION

Scrub typhus fever is a disease caused by bacteria called *Orientia tsutsugamushi*. This bacteria is carried by mites called lepto-trombidium also called as chigger. Chigger mites breed in damp areas where vegetation is thick. Scrub typhus fever occurs in people exposed to areas with scrub vegetation where rodents live, such as forest clearings, riverbanks, grassy areas, deserts, and rain forests, especially in parts of Asia and Australia.^[1]

Scrub typhus fever is not spread from person to person. Disease is spread to people by the bite of a mite also called a “chigger” [Figure 1] infected with the bacteria that causes scrub typhus fever. Symptoms usually appear within 10–12 days after exposure but may appear anywhere from 6 to 21 days after exposure. A reddish or pinkish lesion appears at the site of the mite bite, and the person begins to experience headache, fever, chills, and general pains, along with swollen lymph glands. About 1 week after the start of the fever, a pinkish rash develops over the skin of the trunk and may extend to the arms and leg. When untreated, scrub typhus can be fatal, but the course of the disease can be arrested by the administration of chloramphenicol or the tetracycline, upon which recovery is prompt and uneventful. Macrolides or rifampicin may also be used. Each year, approximately one million cases are reported worldwide, with untreated cases showing a high fatality rate as high as 30%.^[2]

Nitin Rathod¹, Andrea Janice Fonseca², Ruchika Gupta³,
Aayush Jayswal⁴

¹HOD, Department of Medicine, Training Programme Director for IMT (UK), Nanavati Max superspeciality hospital, Mumbai, Maharashtra, India, ²Clinical associate at Nanavati max superspeciality hospital, Mumbai, Maharashtra, India, ³Resident of IMT programme, Nanavati Max Superspeciality hospital, Mumbai, Maharashtra, India, ⁴Senior Dermatologist resident, Dr. D. Y Patil hospital, Mumbai, Maharashtra, India

Corresponding Author:

Nitin Rathod, Department of Medicine, Nanavati Max Superspeciality Hospital, S.V Road, Vile Parle, Mumbai, Maharashtra, India.
E-mail: drnmrathod@hotmail.com

CASE REPORT

A 32-year-old male patient was transferred from private nursing home to our hospital with multi-organ affection with high fever. The patient was apparently alright 2 weeks ago. He has gone out for picnic in hilly area. When he came back, 5 days after he developed fever. Fever was associated with chill and moderate grade and continuous which increased on the next day and he got admitted to nursing home. He also developed skin rash after admission. He had having skin rash which was maculopapular and generalized without itching [Figures 2 and 3]. It was more on the upper limbs, trunk, and back. He also was having body ache, severe weakness, and anorexia. He was having



Figure 1: Image of the chigger mite (*Orientia tsutsugamushi* vector).

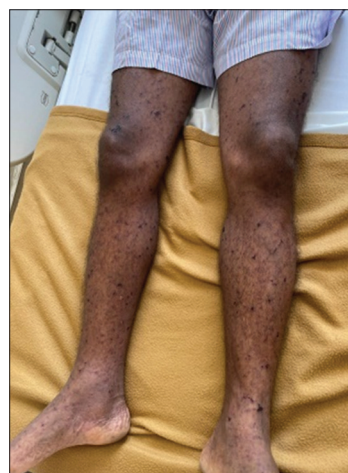

Figure 3: Generalized skin rash over trunk and back.

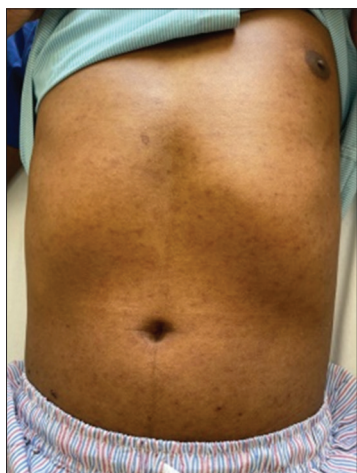


Figure 2: Maculopapular skin rash on upper limbs.

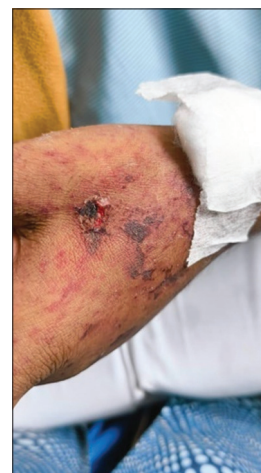

Figure 4: Eschar formation on the patient's left wrist.

dry cough but no breathlessness or chest pain. After 7 days of deteriorating despite treatment at nursing home, he took transfer to our hospital. Physical examination revealed febrile state, 101 F, pulse of 102/min regular, and blood pressure was 110/60. He was having bilateral pedal edema, with skin rashes all over the body with eschar formation on the left arm [Figure 4]. Systemic examination revealed conscious, oriented, and few cervical superficial lymphadenopathies. There was no significant hepatosplenomegaly. There were no other significant systemic abnormalities. His investigations revealed leukocytosis, thrombocytosis, increased liver enzymes with normal prothrombin time/International Normalized Ratio, hyponatremia, and high creatinine level. His tropical fever panel was normal. This includes following polymerase chain reaction (PCR) assay (dengue, chikungunya, leptospira, salmonella, Zika virus, and West Nile virus). His herpes immunoglobulin G (IgG), immunoglobulin M (IgM) antibodies were negative; *Borrelia* IgM was absent; scrub typhus IgM was negative; and triple (human immunodeficiency virus [HIV], hepatitis B virus,

hepatitis C virus [HCV]) antibodies were negative. All details of investigations are given in Tables 1 and 2.

His ultrasound of abdomen and pelvis was normal. His blood culture was normal. His X-ray chest and electrocardiogram were also normal. The patient was diagnosed with scrub typhus based on clinical findings, including the presence of an eschar on the left wrist, supported by serological and PCR testing. Typhi dot for IgG and IgM were negative, and herpes simplex virus (HSV) IgM and HSV IgG were negative. His Weil–Felix titer came very high titer, i.e., 1:320 and scrub typhus PCR was positive. He was on meropenem with antihistaminic and analgesic with intravenous (IV) fluids when he was in private nursing home. The patient was diagnosed as a case of scrub typhus on clinical finding with sign of eschar formation on left wrist (a dry, leathery, and often black or brown crust of dead tissue at the site of bites) and serological grounds with PCR and treated with IV antibiotics (doxycycline and levofloxacin) and additional supportive treatment. He responded well to the treatment with resolution of fever and skin rash and normalization of liver

Table 1: Laboratory parameters

Complete blood count	Day 1	Day 3	Day 5	Day 7	Day 8
Hemoglobin (g/dL)	12.6	11.1	10.8	10.8	11.2
Total leukocyte count (/ μ L)	25350	18820	15510	10990	10470
Platelet count	75k	79k	100k	160 k	210 k
Liver function test					
Total protein (g/dL)	6	5.34	6		
Albumin (g/dL)	2.9	2.6	2.7		
Globulin (g/dL)	3.1	2.7	3.3		
A/G ratio	0.9	1	0.8		
Total bilirubin (mg/dL)	0.907	1.25	0.922		
Direct bilirubin (mg/dL)	0.518	0.603	0.459		
Indirect bilirubin (mg/dL)	0.39	0.65	0.46		
ALP (U/L)	143	100	89.2		
SGPT (U/L)	76.7	53.2	44.8	46.9	48.2
SGOT (U/L)	84.5	47	34.7	31.5	
GGTP (U/L)	54.9				
INR	1.05				
Prothrombin time (seconds)	11.6				
	Day 1	Day 3	Day 5	Day 7	Day 8
Serum creatinine (mg/dL)	2.95	1.57	0.94	0.81	0.75
Serum uric acid (mg/dL)	9.32	6.17	3.44		4.17
Serum calcium (mg/dL)	7.86	7.90	8.28		
Serum phosphorus (mg/dL)	4.43	3.54			
Serum bicarbonate (mEq/L)	21.2	24	24.4		

ALP: Alkaline phosphatase, SGPT: Serum glutamic pyruvic transaminase, SGOT: Serum glutamic oxaloacetic transaminase, GGTP: Gamma-Glutamyl Transferase, INR: International Normalized Ratio

Table 2: Weil–Felix test results on different days of hospitalization.

Parameter	Day 1	Day 3	Day 5
Weil–Felix test			
Proteus Ag OX 19			=1:320
Proteus Ag OX 2			=1:320
Proteus Ag OX K			<1:80

functions, renal functions, and correction of hyponatremia and was discharged after 7 days of admission, on oral doxycycline.

DISCUSSION

Acute febrile illness with skin rash is usually self-limited viral illness with little or no sequelae represent the majority of patient. Thorough history including evolution of rash as well

as geographic, food, animal/insect, and other environmental exposures is imperative in narrowing the diagnosis. Detailed physical examination may reveal features of the rash, eschar formation, and presence of mild hepatosplenomegaly. Scrub typhus is characterized by skin rash initially maculopapular, progressing to petechial and spreading centripetally in patient with high fever, myalgia, and headache with supportive epidemiologic or exposure history (tick bite although patient may not have identified). It may progress to multisystem disease, septic shock, and cardiovascular collapse. Untreated patient will have high mortality rate. The appearance of cutaneous Rickettsia infection is not specific; however, a constellation of findings from the history, arthropod exposure, and clinical presentation may suggest the diagnosis. The classic triad of rickettsial infections is fever, headache, and rash. The morbilliform eruption is not specific and consistent with erythematous macules, with some lesions being more maculopapular) and many of the rickettsial infections will demonstrate an eschar at the bite site.

CONCLUSION

Detail history taking with history of traveling in hilly area/forest area/hiking or foreign travel is important for patient having fever, skin rash, and multi-organ affection. Classical triad including morbilliform eruption plus fever plus necrotic papule (eschar at the tick bite site) should prompt diagnosis of scrub typhus infection. Doxycycline is the treatment of choice for suspected or confirmed rickettsial infections in adults and children; however, in suspected cases, patients should be given injection doxycycline empirically till diagnosis is achieved. Second-generation quinolones (e.g., ofloxacin and ciprofloxacin) and chloramphenicol caused fewer adverse events than doxycycline.^[3]

REFERENCES

- Warrell Clare E, Osborne J, Nabarro L, Gibney B, Carter DP, Warner J, *et al.* Imported rickettsial infections to the United Kingdom, 2015–2020. *J Infect* 2023;86:446–52.
- Richards AL, Jiang J. Scrub typhus: Historic perspective and current status of the worldwide presence of *Orientia* species. *Trop Med Infect Dis* 2020;5:49.
- Zeng BS, Zeng BY, Hung CM, Kuo HC, Chen YW, Suen MW, *et al.* The efficacy and tolerability of antibiotics in scrub typhus: An updated network meta-analysis of randomized controlled trials. *Int J Infect Dis* 2022;122:461–8.

How to cite this article: Rathod N, Fonseca AJ, Gupta R, Jayswal A. Acute Febrile Illness with Skin Rash with Multiorgan Affection Presented as Scrub Typhus – A case report. *Bombay Hosp J* 2024;66(3):22–24.

Source of support: Nil, **Conflicts of interest:** None

This work is licensed under a Creative Commons Attribution 4.0 International License. The images or other third party material in this article are included in the article's Creative Commons license, unless indicated otherwise in the credit line; if the material is not included under the Creative Commons license, users will need to obtain permission from the license holder to reproduce the material. To view a copy of this license, visit <http://creativecommons.org/licenses/by/4.0/> © Rathod N, Fonseca AJ, Gupta R, Jayswal A. 2025.